

Case Report

Vesicovaginal Fistula Failing Multiple Surgical Attempts Salvaged Laparoscopically Without an Interposition Omental Flap

John R. Miklos, MD*, and Robert D. Moore, DO

From Atlanta Urogynecology Associates, Alpharetta, Georgia (all authors).

ABSTRACT Failed vesicovaginal fistula repairs are often considered complicated and are thus relegated to an abdominal approach using an interposition omental flap. We report our successful laparoscopic approach without use of an omental flap in a patient with multiple recurrences of a vesicovaginal fistula. *Journal of Minimally Invasive Gynecology* (2012) 19, 794–797 © 2012 AAGL. All rights reserved.

Keywords: Bladder fistula; Failed fistula; Laparoscopic fistula; Laparoscopic vesicovaginal fistula repair; Latzko; O’Conor; Omental flap; Recurrent fistula; Urogenital fistula; Vaginal fistula; Vesicovaginal fistula

DISCUSS You can discuss this article with its authors and with other AAGL members at <http://www.AAGL.org/jmig-19-6-12-00256>



Use your Smartphone to scan this QR code and connect to the discussion forum for this article now*

* Download a free QR Code scanner by searching for “QR scanner” in your smartphone’s app store or app marketplace.

Vesicovaginal fistula (VVF) can be surgically repaired via a vaginal, abdominal, or laparoscopic approach. The approach used is determined primarily on the basis of surgeon experience, and for most VVF repairs, the preferred approach is vaginal. The abdominal approach is often reserved for complicated cases such as those involving difficult vaginal access, high VVF, ureteral involvement necessitating reimplantation, or the need for a concomitant abdominal procedure [1].

Abdominal approaches can be intraperitoneal or extraperitoneal. In the extraperitoneal approach, a suprapubic incision is made, and cystotomy is normally performed through the dome of the bladder. With an extraperitoneal approach, it is impossible to use the omentum as an interposition graft. Although little research has been performed to confirm this practice, some surgeons recommend that an interposition vascular graft be used in all patients undergoing an abdominal approach to VVF repair [2–4], whether complicated or uncomplicated.

The authors have no commercial, proprietary, or financial interest in the products or companies described in this article.

Corresponding author: John R. Miklos, MD, Atlanta Urogynecology Associates, 3400-C Old Milton Pkwy, Ste 330, Alpharetta, GA 30005.
E-mail: johnRmiklos@yahoo.com

Submitted May 23, 2012. Accepted for publication August 9, 2012.
Available at www.sciencedirect.com and www.jmig.org

1553-4650/\$ - see front matter © 2012 AAGL. All rights reserved.
<http://dx.doi.org/10.1016/j.jmig.2012.08.768>

Case Report

A 37-year-old woman had symptoms of a VVF and continuous urine leakage for 1 year despite bladder injury repair multiple times. She reported that she had sustained a bladder injury that was repaired during total abdominal hysterectomy. The hysterectomy was performed because of menorrhagia and endometriosis.

Three weeks after the surgery, a VVF was diagnosed, and 9 weeks later the patient underwent a Latzko procedure performed by a urogynecologist. One week later the fistula had recurred, as confirmed via cystourethrography. Five months later, the patient underwent a second Latzko procedure performed by the same urogynecologist, and after suprapubic catheter drainage for 6 weeks, the catheter was removed. Three months after removal of the catheter, the VVF recurred, as confirmed via cystourethrography. Seven months after the last surgical failure, the urogynecologist made a final attempt at repair using fibrin glue, which was unsuccessful. The surgeon then recommended transabdominal VVF repair with an interposition omental flap; however, the patient preferred a less invasive option.

Three months later the patient was seen in our office for evaluation, and after giving informed consent, she opted for a laparoscopic approach to layered closure VVF repair without an omental flap. Our laparoscopic approach to layered closure VVF repair using an omental

flap after a failed fistula repair has been described previously [5], and is not a modification of the O'Connor technique [6].

The patient was taken to the operating room, where cystoscopy was performed and a ureteral stent was placed through the fistula and delivered through the vagina to facilitate identification during dissection. Open laparoscopy was performed at the inferior edge of the umbilicus, where a 10-mm port was placed to accommodate the laparoscope. Three additional ports were placed under direct vision. A 5-mm port was placed suprapubically and in the right paramedian, and a 10-mm port was placed in the left paramedian area. After adhesions were lysed and adequate access to the vesicovaginal area was achieved, an end-to-end anastomosis sizer was placed in the vagina to elevate the apex and facilitate dissection. The bladder was retrograde filled with normal saline solution until the vesicovaginal reflection could be adequately identified. The vesicovaginal space was dissected using endoscopic scissors. Laparoscopic identification of the ureteral stent confirmed entry into the fistulous tract (Fig. 1). The tract was excised from both the vaginal and bladder areas, and dissection was continued approximately 2 cm distal to the site, enabling complete separation of the bladder and urethra from the newly excised fistula area (Fig. 2).

The vagina was closed using a single layer of 2/0 polyglactin 910 (Vicryl) suture, and the bladder was closed using a double layer of 3/0 polyglactin 910 suture in a figure-of-eight fashion (Fig. 3). After the first layer of bladder closure, the bladder was retrograde filled with 400 mL indigo carmine–sterile water solution, and a clean, dry, 4 × 4-cm sponge was placed in the cul-de-sac and on the bladder suture line. The sponge was removed, and no evidence of indigo carmine was noted on the sponge. After confirming good primary closure of the bladder, a second-layer

Fig. 1

Placement of a stent in the vesicovaginal fistula enables easier identification and dissection of the fistula. The dissection between the bladder and vagina is almost complete, and the stent has been cut in half, with both sides of the fistula (i.e., bladder and vagina) still with half a stent.

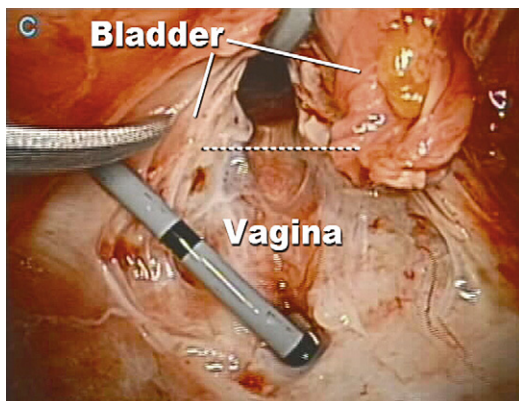
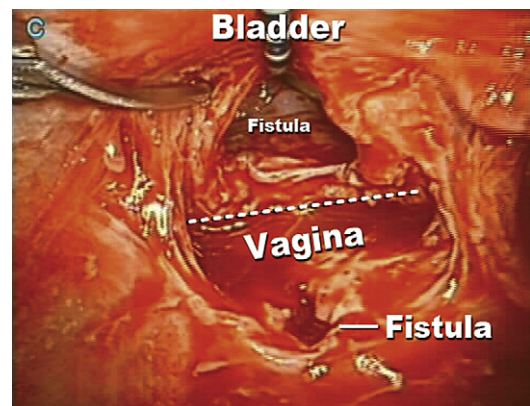


Fig. 2

Further dissection between the bladder and away from the vagina enables complete separation of the fistula tract in the vagina and bladder.



closure was performed using 3-0 polyglactin 910 suture. Again, the bladder suture line integrity test was performed by filling the bladder with indigo carmine–sterile water solution and placing a clean, white, 4 × 4-cm sponge in the cul-de-sac and on the suture line. Again no evidence of indigo carmine was noted on removal of the sponge. All suturing was performed laparoscopically using extracorporeal knot tying. Cystoscopy was performed after each layer of bladder closure, and bilateral ureteral patency was confirmed. The suprapubic catheter was removed 14 days after the repair, only after confirming success via cystoscopy, retrograde filling of the bladder, and inspecting the vagina for leakage. At 2 years after the procedure, the patient has had no recurrence of spontaneous urine leakage.

Fig. 3

A layered closure technique is accomplished by closing the vagina using a single-layer closure, and the bladder using double-layer closure. Note the distance between the suture lines on the vagina and the bladder.

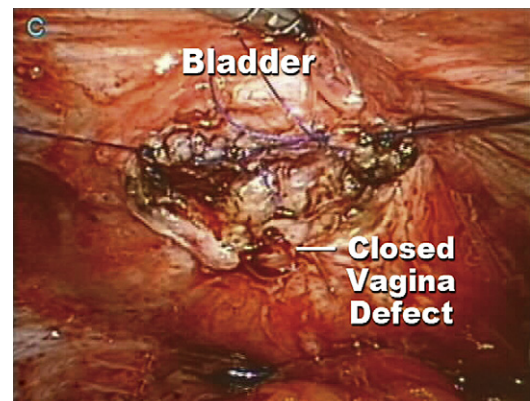
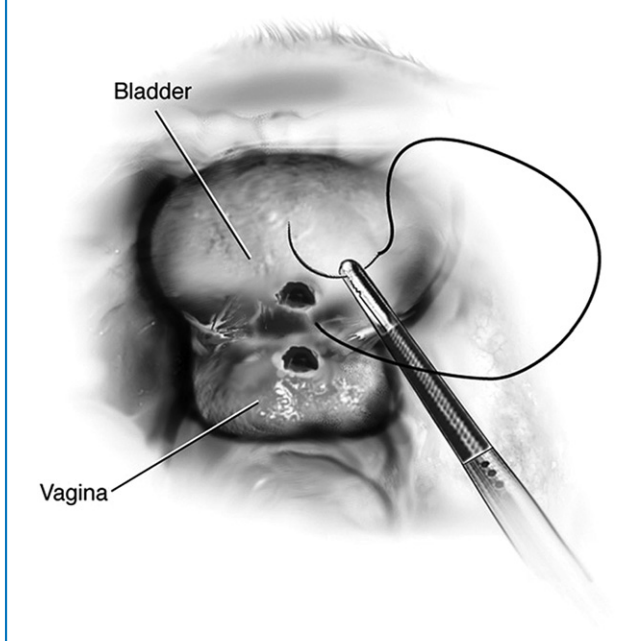
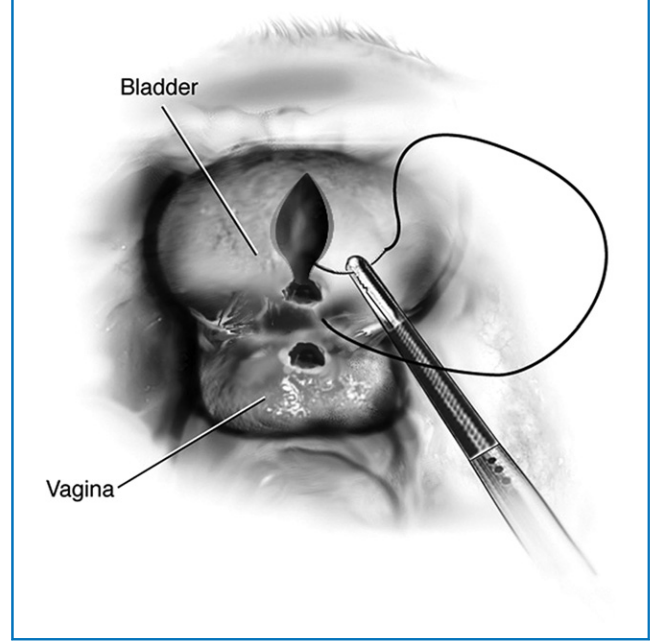


Fig. 4

Extraperitoneal vesicovaginal fistula dissection reveals minimal dissection and trauma to the bladder wall.

**Fig. 5**

Bivalving (O'Conor technique) the bladder to identify the fistula results in a larger defect in the bladder wall.



Discussion

Failed VVF repair is often labeled as complicated repair and thus is relegated to the interposition omental flap paradigm. Some surgeons believe interposition flaps should be used not only in complicated VVF repairs but also in all VVF repairs, to enhance surgical success [3,4]. As logical as this proposal might seem, prospective randomized clinical trials have not been performed to establish this practice as the standard of care. We the authors believe the most important aspects of VVF repair are adequate dissection and separation of the fistulized organs (i.e., the bladder and vagina) and meticulous repair and closure of each organ with emphasis on the organ of higher pressure (i.e., the bladder). This is why we perform double-layer closure of the bladder. We also believe that an omental flap is not necessary in uncomplicated VVF repairs if the closure is truly “watertight” intraoperatively and the bladder is allowed to heal in a low-pressure setting by maintaining adequate catheterization.

We believe no surgical procedure, including placement of an interposition omental graft, is without potential complications. Although the risk of interposition grafts might seem low, placing an interposition graft might be a cause of intraoperative complications such as intravesical suture placement and of postoperative complications including: prolonged paralytic ileus [4], bowel obstruction, increase in peritoneal adhesions, and subsequent chronic pelvic pain.

Although we have presented our extraperitoneal dissection and layered closure technique without bivalving the

bladder in other case studies in the 1990s [5,7], the scientific literature has implicated that this laparoscopic VVF repair technique is a modification of the O'Conor technique [1,2]. The extraperitoneal dissection and layered closure technique is not a modification of the O'Conor technique and uses the basic principles of fistula repair as cited by Couvelaire [8] in the 1950s. Using the extraperitoneal vesicovaginal dissection (Fig. 4) and layered closure technique discussed herein, one minimizes the bladder defect by negating the need of bivalving the bladder. Bivalving, as in the O'Conor technique, increases the size of the bladder defects (Fig. 5) and, in theory, increases the chance of failure of the VVF repair. This theory can be supported by fistula experts who have documented that there is a greater chance of surgical failure with larger fistulas [9], and others have reported great success using the nonbivalving intraperitoneal extravescical layered closure technique with and without omental flaps [10–12]. We believe the present case is the first report of successful VVF repair after multiple VVF recurrences, performed using a nonbivalving multilayer closure technique without an omental flap.

References

1. Stanford E, Romanzi L. Vesicovaginal fistula: what is the preferred closure technique? *Int Urogynecol J*. 2012;23:383–385.
2. Meeks G, Roth T. Vesicovaginal and urethrovaginal fistulas. *Glob Libr Women's Med* [serial online]. <http://dx.doi.org/10.3843/GLOWM.10064>.
3. Evans DH, Madjar S, Politano VA, et al. Interposition flaps in transabdominal vesicovaginal fistula repairs: are they really necessary? *Urology*. 2001;57:670–674.

4. Singh V, Sinha RJ, Mehrotra S, Sankhwar SN, Bhatt S. Repair of vesicovaginal fistula by the transabdominal route: outcome at a north Indian tertiary hospital. *Int Urogynecol J*. 2012;23:411–416.
5. Miklos JR, Sobolewski C, Lucente V. Laparoscopic management of recurrent vesicovaginal fistula. *Int Urogynecol J Pelvic Floor Dysfunct*. 1999;10:16–17.
6. O'Connor VJ, Sokol JK, Bulkley GJ, et al. Suprapubic closure of vesicovaginal fistula. *J Urol*. 1973;109:51–54.
7. Miklos JR. Laparoscopic treatment of a vesicouterine fistula. *J Am Assoc Gynecol Laparosc*. 1999;6:339–341.
8. Couvelaire R. Reflections on a personal statistic of 136 vesicovaginal fistulas. *J Urol Med Chir*. 1953;59:150–160.
9. Ayed M, El Atat R, Hassine LB, Sfaxi M, Chebil M, Zmerili S. Prognostic factors of recurrence after vesicovaginal fistula repair. *Int J Urol*. 2006;13:345–349.
10. Das Mahapatra P, Bhattacharyya P. Laparoscopic intraperitoneal repair of high-up urinary bladder fistula: a review of 12 cases. *Int Urogynecol J Pelvic Floor Dysfunct*. 2007;18:635–639.
11. Lee JH, Choi JS, Lee KW, Han JS, Choi PC, Hoh JK. Immediate laparoscopic nontransvesical repair without omental interposition for vesicovaginal fistula developing after total abdominal hysterectomy. *JSLS*. 2010;14:187–191.
12. Abdel-Karim AM, Mousa A, Hasouna M, Elsalmy S. Laparoscopic transperitoneal extravesical repair of vesicovaginal fistula. *Int Urogynecol J*. 2011;22:693–697.